

Brain Tumor Detection using GLCM with the help of KSVM

Megha Kadam, Prof.Avinash Dhole

Abstract— Brain tumor is a very harmful disease for human being. A tumor is a mass of tissue that's formed by an accumulation of abnormal cells. The location of tumors in the brain is one of the factors that determine how a brain tumor affects an individual's functioning. Image processing is an active research area in which medical image processing is a highly challenging field. For medical diagnosis of the inner portions of the human body Medical imaging techniques are used. MRI Imaging play an important role in brain tumor for analysis, diagnosis and treatment planning. Brain tumor detections are using MRI images is a challenging task, because the complex structure of the brain. In this paper we detect brain tumor using GLCM with KSVM. We used four different classes, Extract feature through GLCM and then KSVM is applied. Which gives good classification rate.

Index Terms— SVM (Support Vector Machine), GLCM (Gray Level Co-Occurrence Matrix), MRI (Magnetic resonance imaging), KSVM (Kernel Support Vector Machine), KNN(K-nearest neighbor)

I. INTRODUCTION

In magnetic resonance imaging (MRI) large magnet and radio waves used to look at organs and structures inside your body. MRI is used in Health care professionals to diagnose a variety of conditions[10]. MRIs are very useful for examination of the brain. The Support Vector Machine (SVM) is a state-of-the-art classification method. Due to its high accuracy, the SVM classifier is widely used in bioinformatics (and other disciplines). It deal with high-dimensional data such as gene expression, and flexibility in modeling diverse sources of data. SVMs belong to the general category of kernel methods[4]. A kernel method is an algorithm that depends on the data only through dot-products. The GLCM is a tabulation of how often different combinations of pixel brightness values (grey levels) occur in an image.

II. LITERATURE REVIEW

1. Nitish Zulpe¹ and Vrushen Pawar² "GLCM Textural Features for Brain Tumor Classification" May 2012, Department of computational science, SRTM University Nanded, Maharashtra.

-In this paper, In medical image processing automatic recognition system for medical image is challenging task. For diagnosis purpose computed tomography[1], MRI etc, are used. Brain tumor classification is very important phase in medical field for future treatment. There is need of such a automated recognition system because Human interpretation

of large number of MRI slices (Normal or Abnormal) may leads to miss-classification, that can classify the type of brain tumor. In this research work, they used four different classes of brain tumors and extracted the GLCM based textural features of each class, and they applied to two layered Feed forward Neural Network, which gives 97.5% classification rate.

2. Y. Zhang and I. Wu" an mri brain images classifier via principal Component analysis and kernel support Vector machine", 2012, School of Information Science and Engineering, Southeast University, Nanjing, China.

-In this paper, To classify a given MR brain image as normal or abnormal they presented a novel method. From images the proposed method first employed wavelet transform to extract features. To reduce the dimensions of features apply principle component analysis (PCA)[2]. These features were submitted to a kernel support vector machine (KSVM). The strategy of K-fold strained cross validation was used to enhance generalization of KSVM.

3. "Detection and Classification of Brain Tumor in MRI Images" Prachi Gadpayle and Prof.P.S.Mahajani. July 2013

- In this, method involves processing of MRI images that are affected by brain tumor, for detection and classification of brain tumors. Preprocessing, segmentation, morphological etc image processing techniques used for the detection of tumor. For extracting features from the MRI image texture feature extraction method is used[3][9]. Features are extracted using Gray Level Co occurrence Matrix. BPNN and KNN Classifier is used after feature extraction for the classification of brain into normal and abnormal images.

4. "Classification of MRI Brain Image using SVM Classifier" Mrs.M.C.Hingane. March 2015 Department of Computer Engineering PDEA's COEM, Pune.

- In this paper describe the design and development of content-based image retrieval (CBIR) system. In order to protect the semantic consistency among the retrieved images this system enables both multi-image query and slide-level image retrieval. From large collection of image database visual queries is used for finding relevant image. Medical images have led to growth in large image collection. CBIR[4] is used to enhance the medical image retrieval for diagnostics, research and teaching purposes. The system performance[10] is improved by the multiple image queries instead of single image query. By median filter to remove the noise the Pre-processing of the query image is done. For feature extraction technique the filtered image is given as input which is a transformation of input image into set of features such as texture and shape. The Gray level co-occurrence matrix

Megha Kadam, Female, RITEE college, CSVTU, Raipur, Address-RITEE, Raipur, C.G., India, Mob.-9617847843

Prof.Avinash Dhole, Male, RITEE college, CSVTU, Raipur, Address-RITEE, Raipur, C.G., India, Mob.-9617847843

algorithm is used for feature extraction, that contains information about the position of pixels having similar gray level values. To group items that have similar feature values into three categories such as normal, benign and malignant is done by SVM. Then SVM classifier is followed by KNN (K-nearest neighbor) which search the corresponding database index will be computed by similarity feature matching.

III. METHODOLOGY

3.1 Magnetic Resonance Imaging

For extremely accurate method of disease detection throughout the body an MRI scan can be used and is most often used after the other testing fails to provide sufficient information to confirm a patient's diagnosis. The head can be seen as bleeding or swelling. The abnormalities often found include brain aneurysms, stroke, tumors of the brain, as well as tumors or inflammation of the spine.

Class I (Astrocytoma)

The patient was a young man; the mixed signal intensity on proton density (PD) and T2-weighted (T2) images is demonstrated by MR [1]. Contrast enhancement can be show the lesion to contain cystic elements. an anterior border of high uptake can be shown by thallium images , consistent with a small region of tumor recurrence[5].

Class II (Meningioma)

The patient was an old man who had several month history of progressive difficulty walking. He had noted that his left lower extremity weak and feel some difficulty with memory and concentration [1]. He was alert and oriented, but had slow and hesitating speech. He could remember only 1 of 3 objects in few minutes.

Class III (Metastatic Bronchogenic Carcinoma)

This 42 year old woman at began having headaches and she uses tobacco, few month before these images were obtained. a large mass with surrounding edema shown in Brain images [1], and compression of adjacent midbrain structures. The high signal intensity on proton density (PD) and T2-weighted (T2) images is demonstrated by MR which is at large left temporal region

Class IV (Sarcoma)

The patient was a younger man who was admitted for resection of Ewing's sarcoma (peripheral/primitive neuroepithelial tumor- PNET[1]). He was noted Vaguely described visual difficulty and retrospectively to have begun approximately one month prior to admission.

3.2 Preprocessing

Our method consists of three stages:

- Step 1. Preprocessing (including feature extraction and feature reduction);
- Step 2. Training the kernel SVM;
- Step 3. Submit new MRI brains to the trained kernel SVM, and output the prediction.

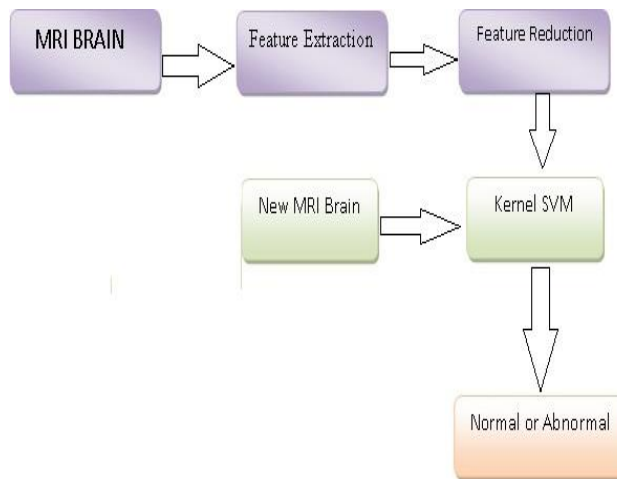
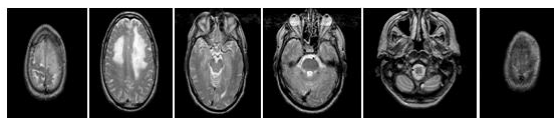


Fig 01 Preprocessing extraction to prediction

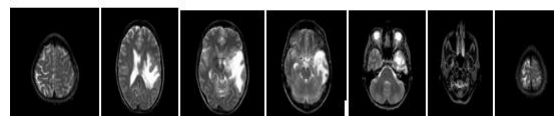
3.3 Dataset

For this experimental work Four different classes of Brain tumor MR images are used, in which samples are collected from the Whole Brain Atlas (WBA). Every image is having the exact size of 256x256 in axial view.

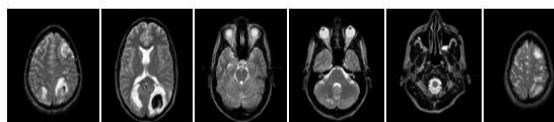
1 Class (Menengioma)



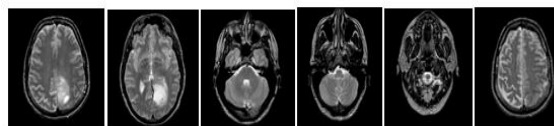
2 Class (Meta)



3 Class (Sarcoma)



4 Class (Spect)



3.4 Feature Extraction

For extracting textural feature from images Gray Level Co-Occurrence Matrix (GLCM) has proved to be a popular statistical method is used[10]. According to co-occurrence matrix to extract the characteristics of texture statistics of remote sensing image, 22 textural features measured from this probability matrix.

- In these 22 important features will be -
- f1. Uniformity / Energy / Angular Second Moment
- f2. Entropy (done)
- f3. Dissimilarity (done)
- f4. Contrast / Inertia (done)
- f5. Inverse difference

- f6. Correlation
- f7. Homogeneity / Inverse difference moment
- f8. Autocorrelation
- f9. Cluster Shade
- f10. Cluster Prominence
- f11. Maximum probability
- f12. Sum of Squares
- f13. Sum Average
- f14. Sum Variance
- f15. Sum Entropy
- f16. Difference variance
- f17. Difference entropy
- f18. Information measures of correlation (1)
- f19. Information measures of correlation (2)
- f20. Maximal correlation coefficient
- f21. Inverse difference normalized (INN)
- f22. Inverse difference moment normalized (IDN)

- [5] Cocosco, C., Zijdenbos, A. P., and Evans, A. C., 2003. A fully automatic and robust brain MRI tissue Classification method, *Medical Image Analysis* 7, pp. 513-527
- [6] Fletcher-Heath, L. M., Hall, D. L. O., Goldgof, B., F. Murtagh, R., 2001. Automatic
- [7] Smeulders, A. W. M., Worring, M., Santini, S., Gupta, Content-Based Image Retrieval at the End of the Years, *IEEE Transactions on Pattern Analysis and Machine Intelligence*.
- [8] Arati Kothari, Detection and classification of brain cancer using artificial neural network in MRI images, *World Journal of Science and Technology*, 2012, ISSN: 2231 – 2587.
- [9] Ricci P.E., Dungan D. H., "Imaging of low- and intermediate-grade gliomas", *Seminars in Radiation Oncology*, 2001, 11(2), p. 103-112.
- [10] Kaus *et.al.*, "Automated segmentation of MR images of brain tumors", *Journal of radiology*, vol.218, no.2, pp: 586-591, 2001.
- [11] M. C. Clark, L. O. Hall, D. B. Goldgof, L.P. Clarke, R. P. Velthuizen, and M. S. Silbiger, "MRI Segmentation using Fuzzy Clustering Techniques", *IEEE Engineering in Medicine and Biology*, pp. 730-742, 1994

3.4 Classification

The Support Vector Machine (SVM) is a state-of-the-art classification method. Due to its high accuracy, the SVM classifier is widely used in bioinformatics[8] (and other disciplines). It deals with high-dimensional data such as gene expression, and flexibility in modeling diverse sources of data. SVMs belong to the general category of kernel methods. An algorithm that depends on the data only through dot-products is kernel method. The dot product can be replaced by a kernel function that computes a dot product in some possibly high dimensional feature space. This gives two advantages: First is, the ability to generate non-linear decision boundaries using methods designed for linear classifiers. Second is, the use of kernel functions allows the user to apply a classifier to data that have no obvious fixed-dimensional vector space representation.

IV. CONCLUSION

In this study, we tried to classify the four different classes of tumor types such as Astrocytoma (Spect), Meningioma, Metastatic and Sarcoma. The GLCM textural features used to train the feed forward neural network. The medical decision making system has been designed by the gray level co-occurrence matrices (GLCM), principal component analysis (PCA), and support vector machine as a supervised learning method (SVM) These will help us to get very promising results in classifying the normal images, images with tumor and image of multiple sclerosis.

REFERENCES

- [1] Nitish Zulpe¹ and Vrushen Pawar² "GLCM Textural Features for Brain Tumor Classification" May 2012, Department of computational science, SRTM University Nanded, Maharashtra.
- [2] Y. Zhang and I. Wu "An MRI brain images classifier via principal Component analysis and kernel support Vector machine", 2012, School of Information Science and Engineering, Southeast University, Nanjing, China.
- [3] "Detection and Classification of Brain Tumor in MRI Images" Prachi Gadpayle and Prof. P.S. Mahajani, July 2013
- [4] "Classification of MRI Brain Image using SVM Classifier" Mrs. M.C. Hingane, March 2015, Department of Computer Engineering PDEA's COEM, Pune.